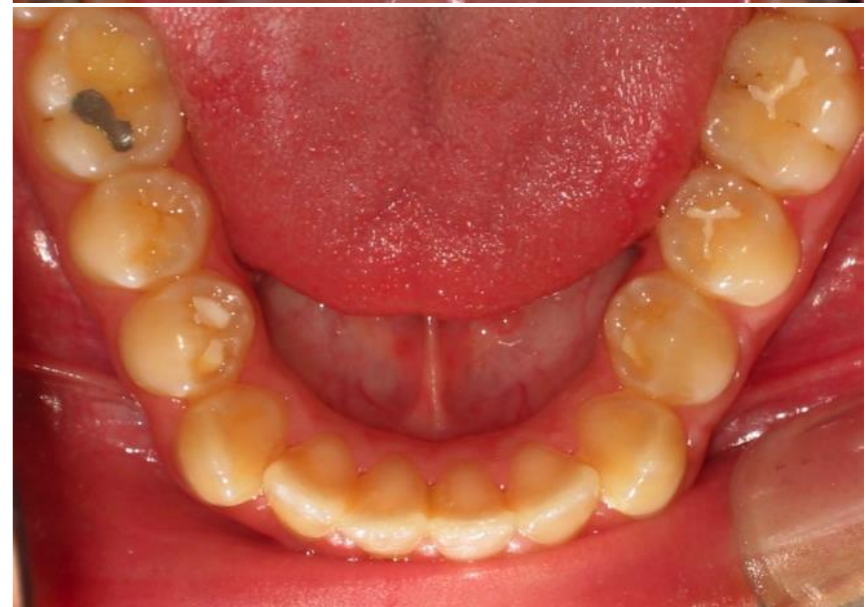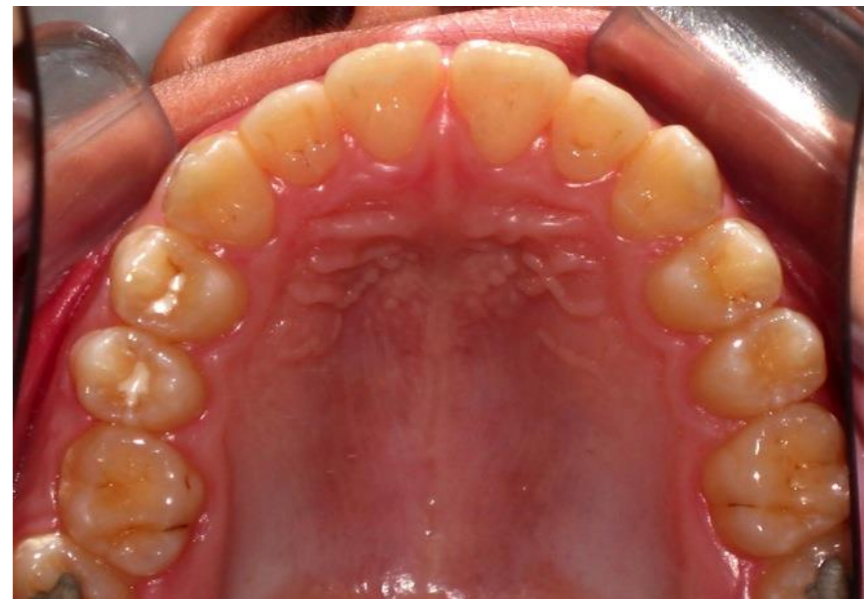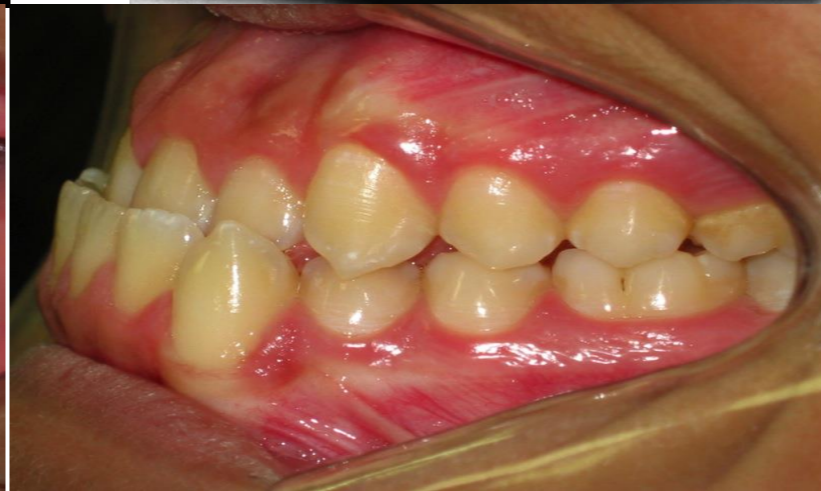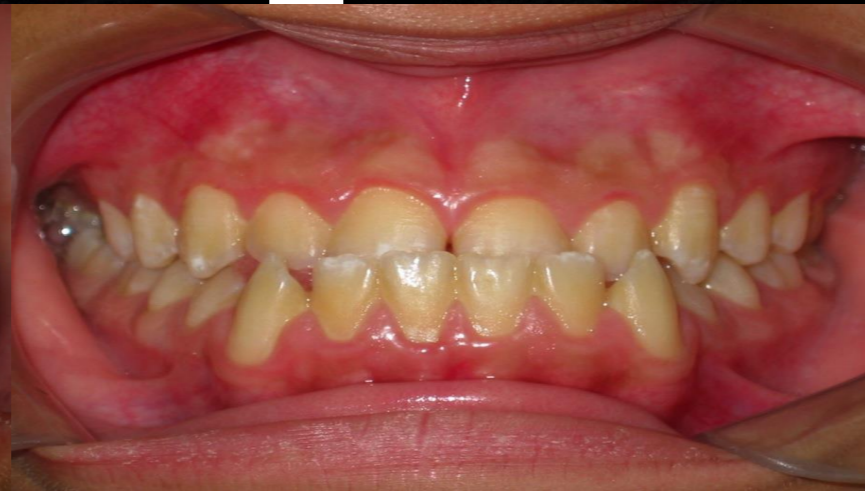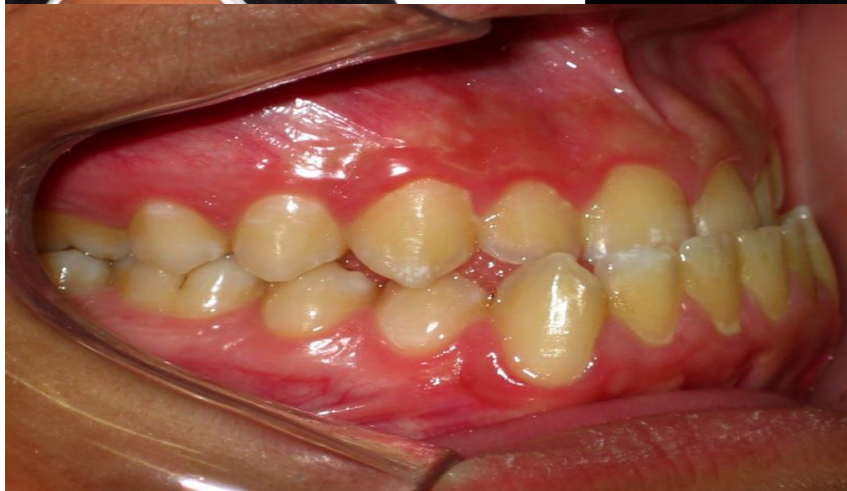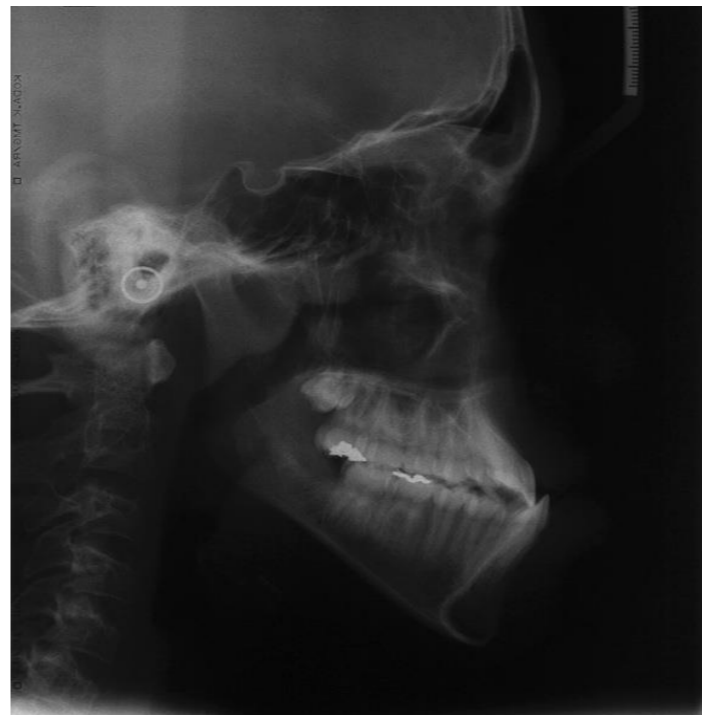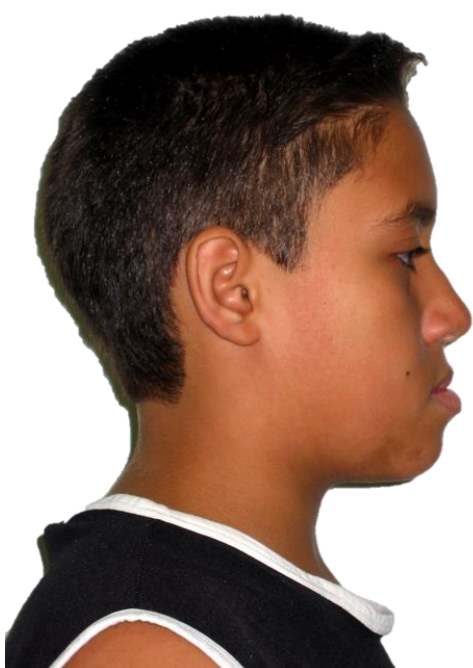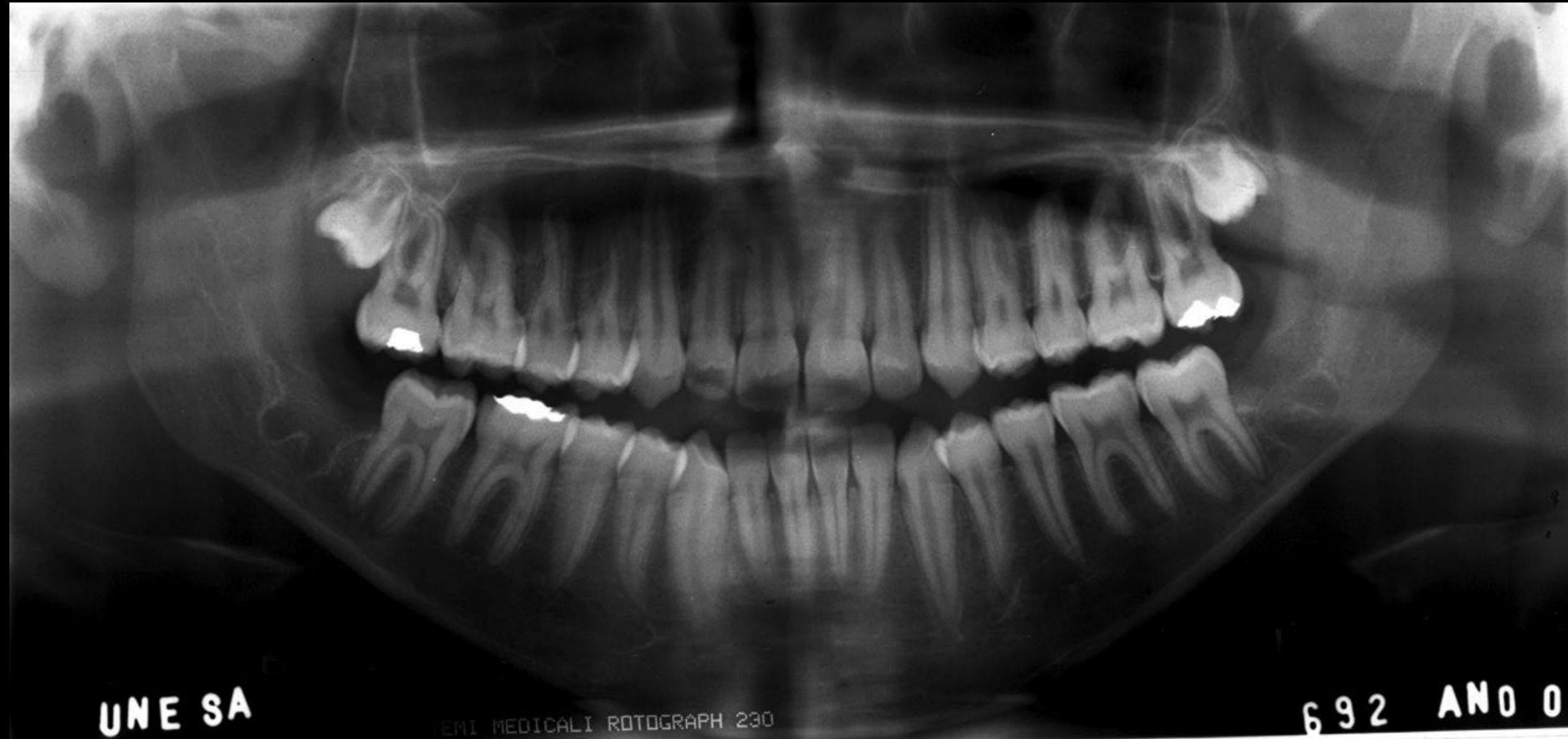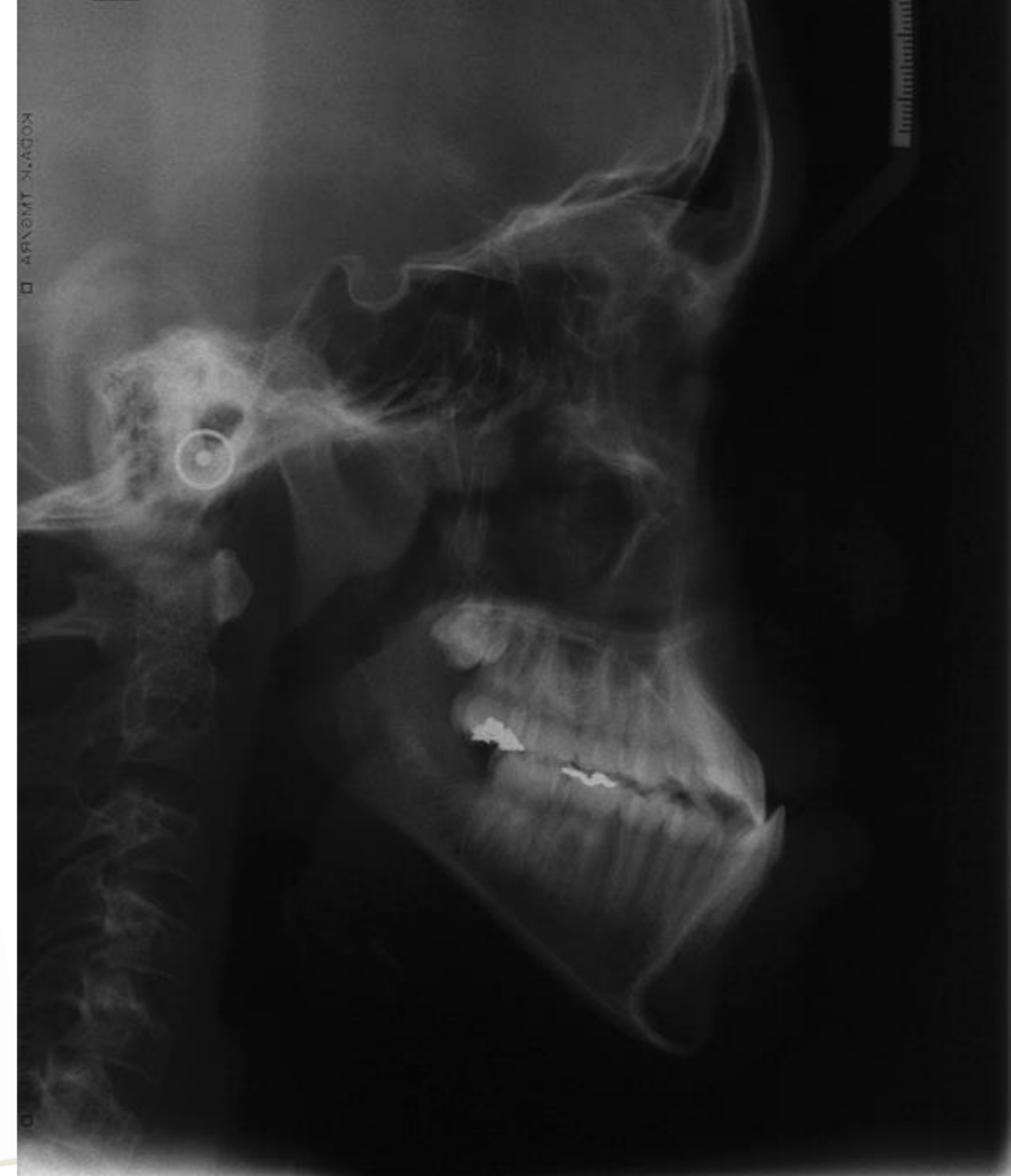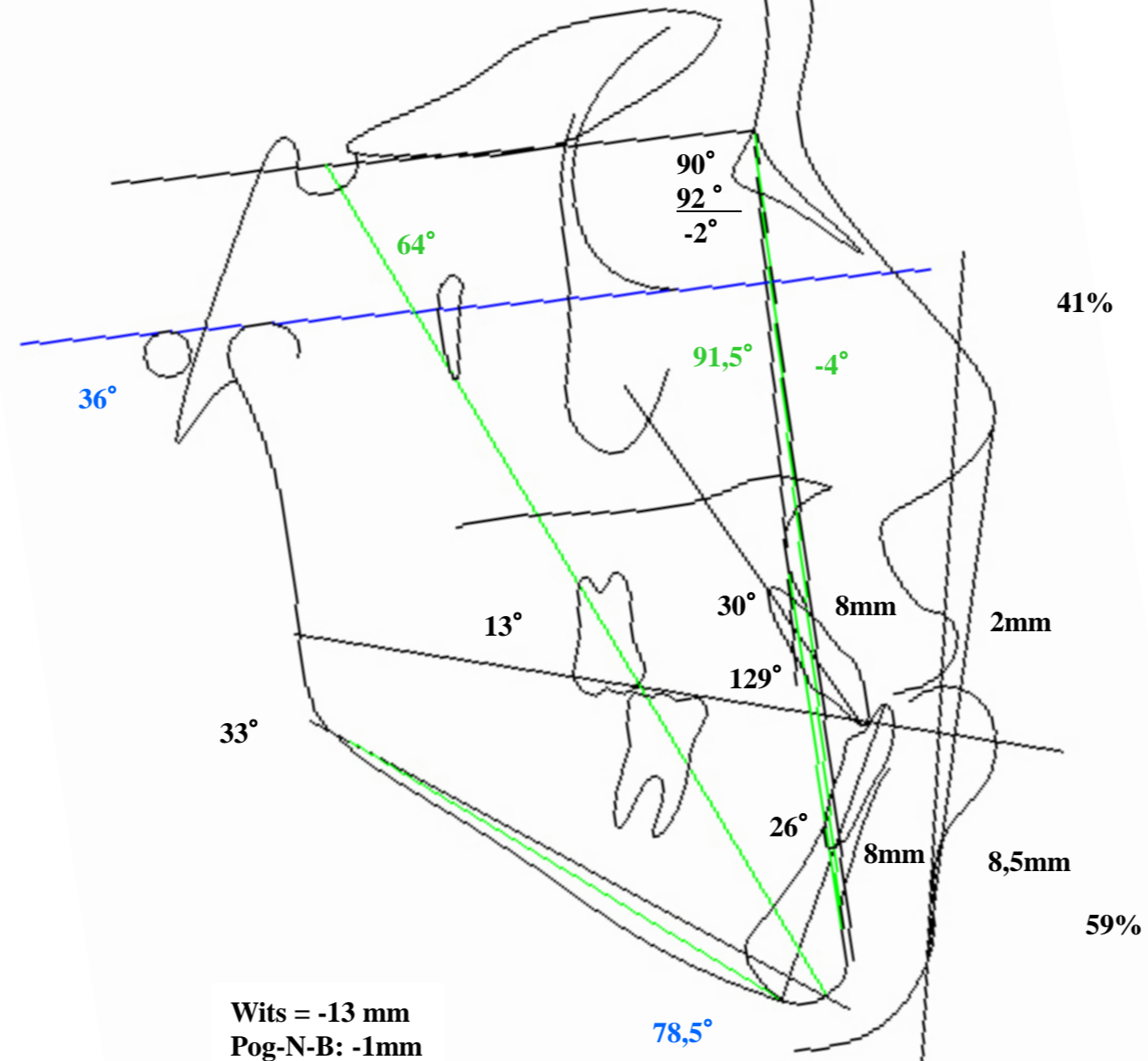




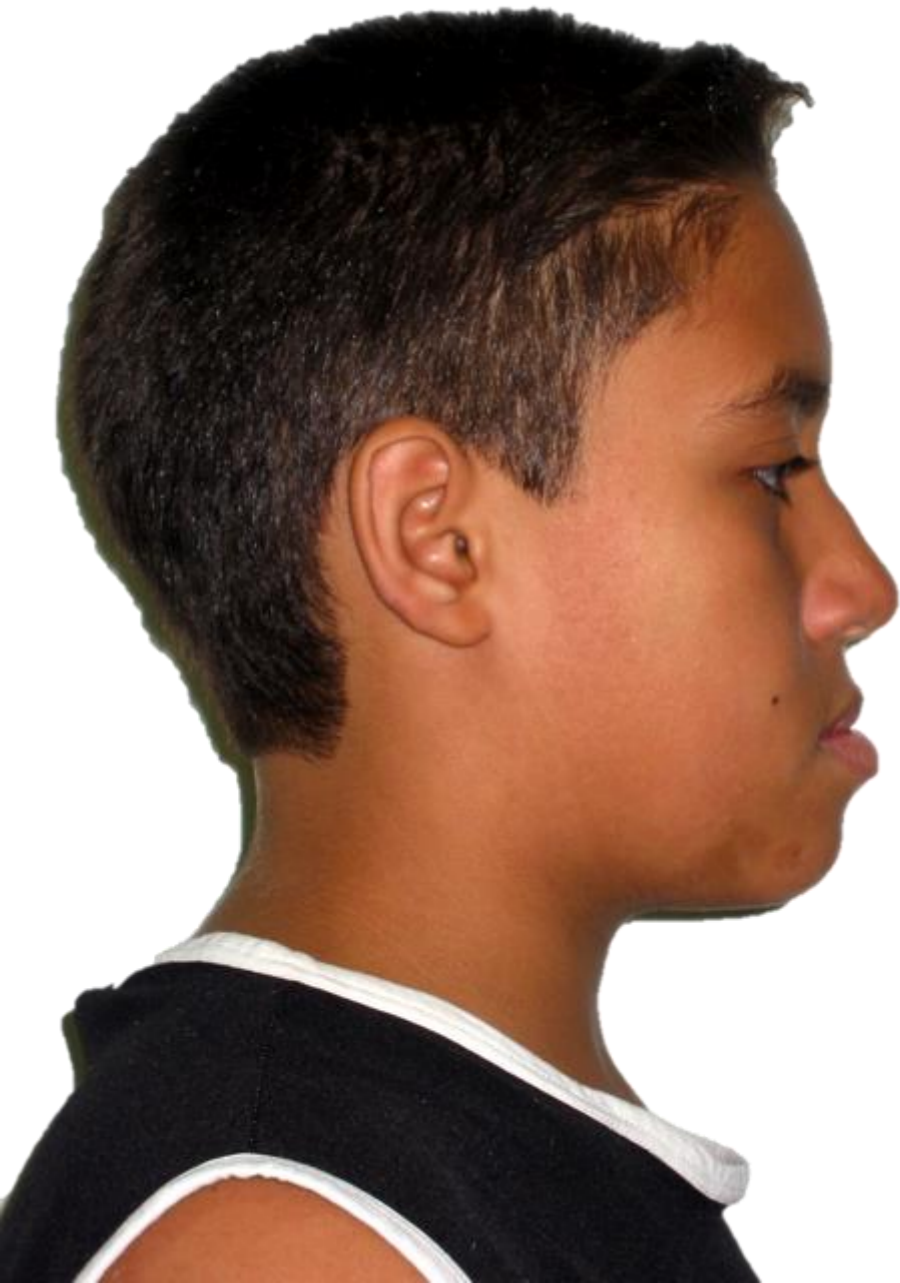ANÁLISE RADIOGRÁFICA



ANÁLISE RADIOGRÁFICA

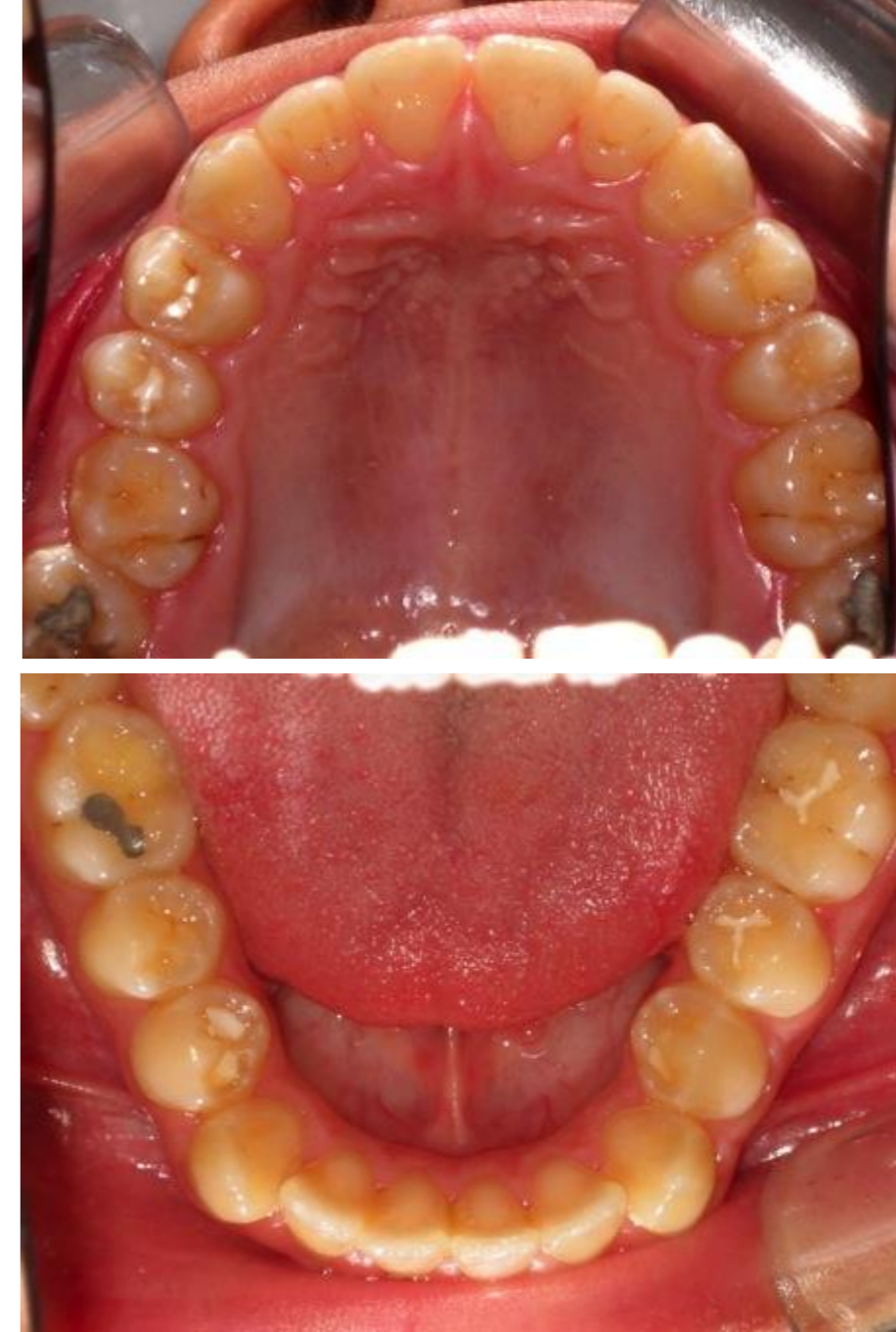

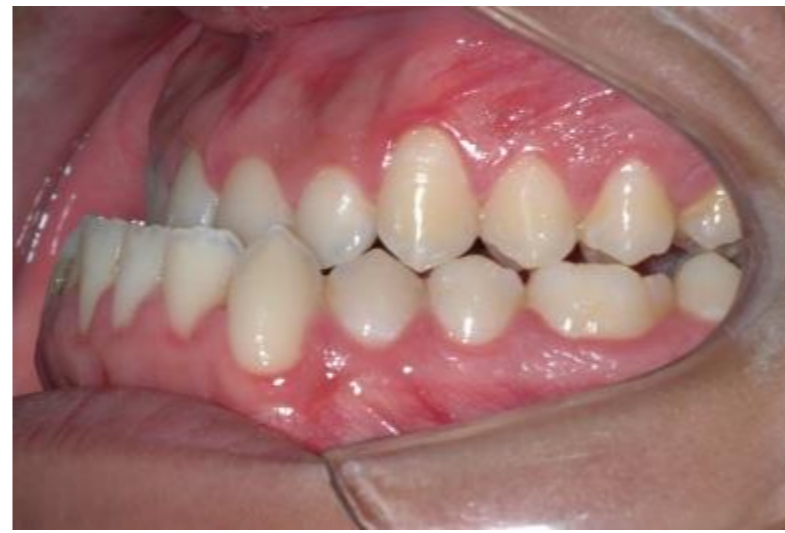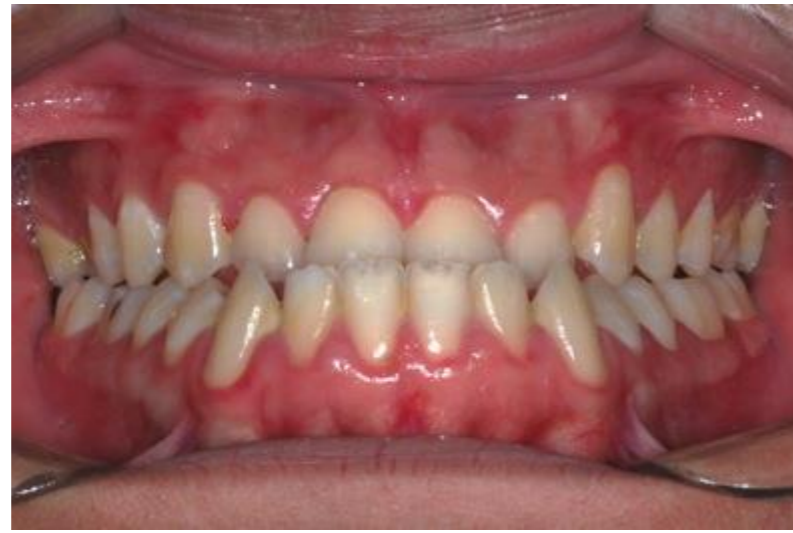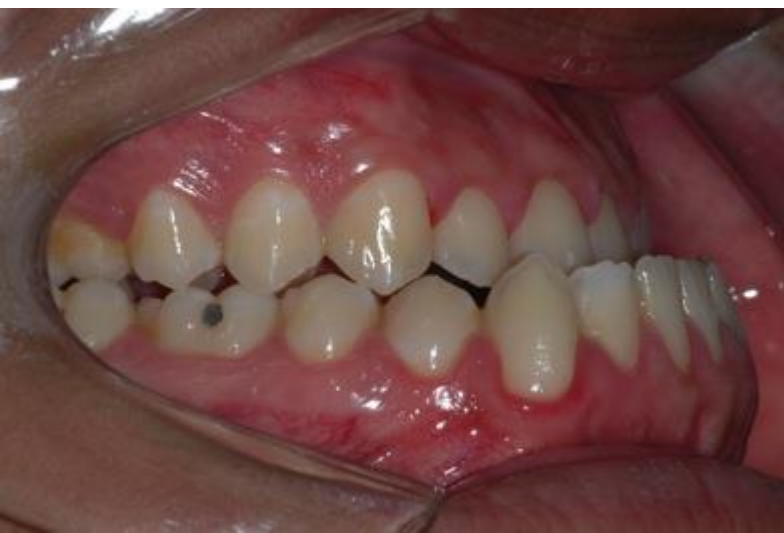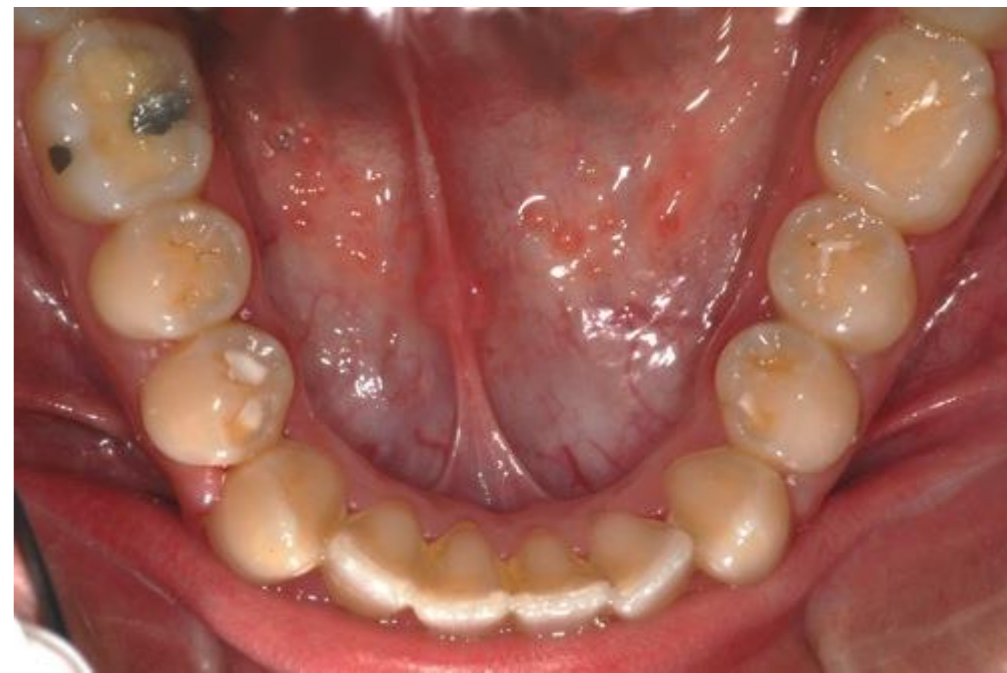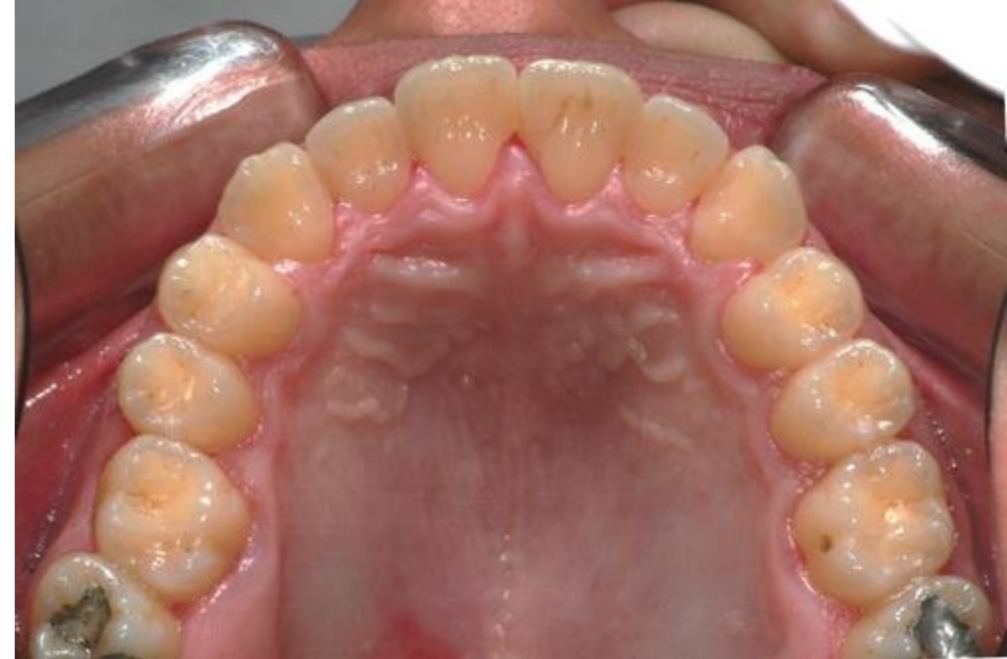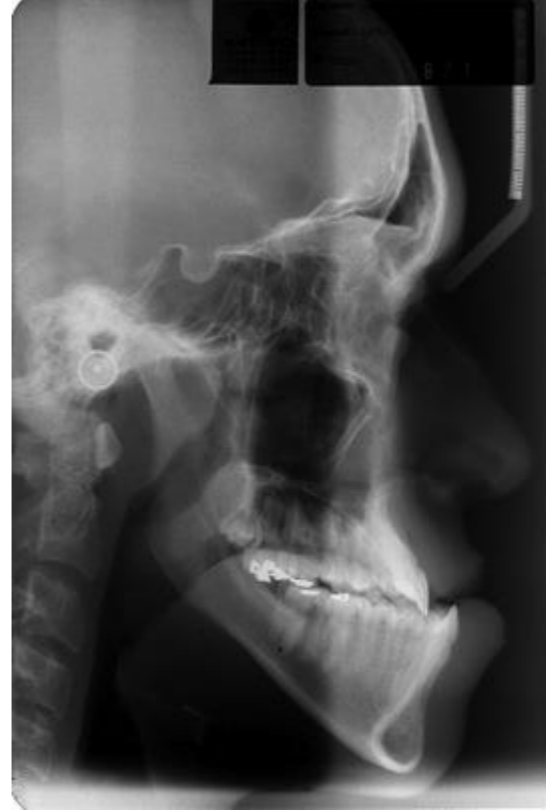PLANO DE TRATAMENTO

Máscara de Protração Maxilar

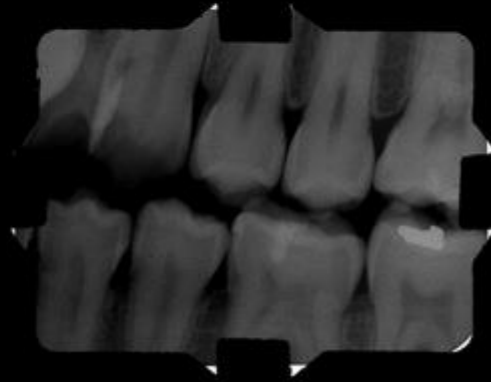
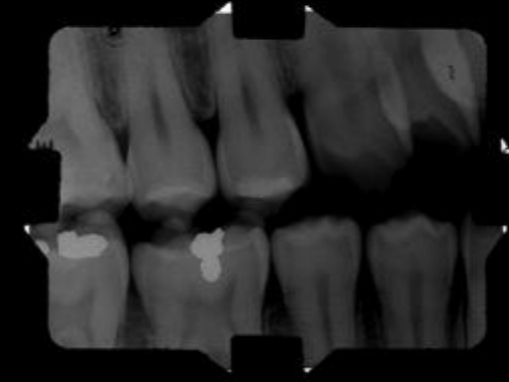
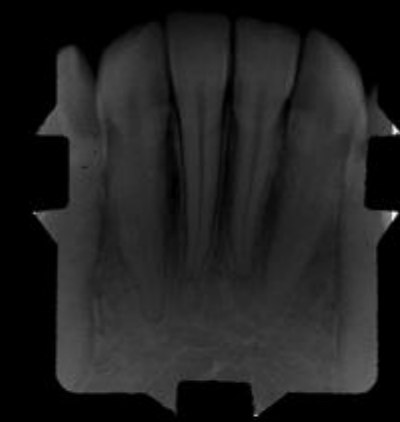
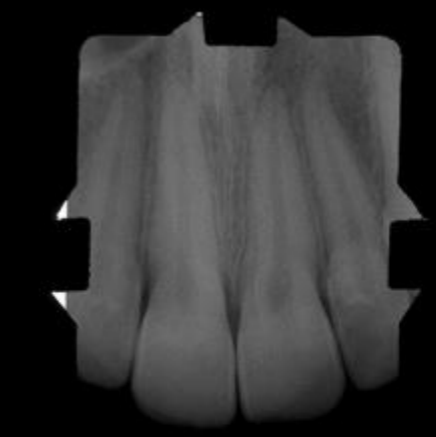
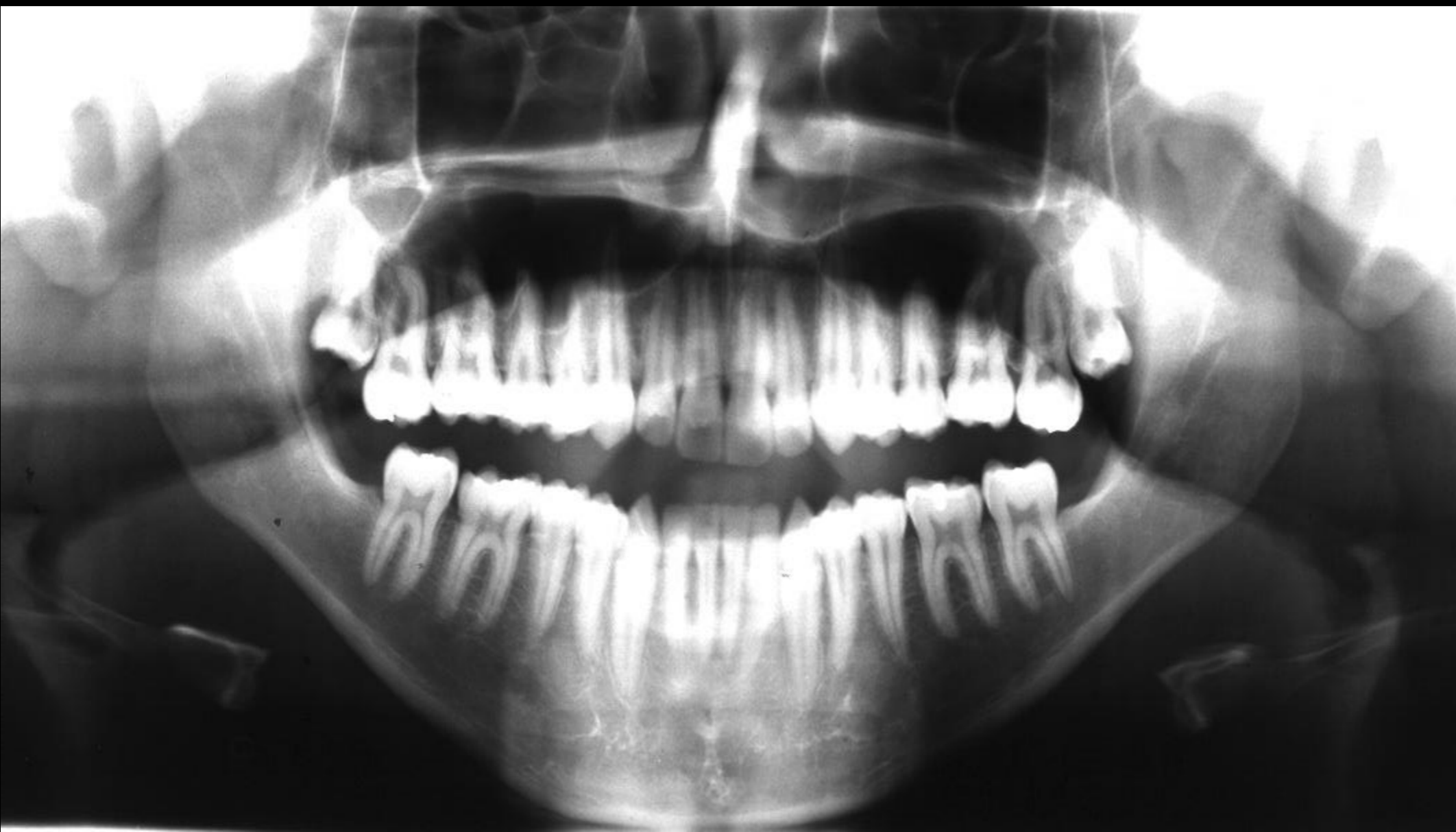X

Aguardar o término do crescimento para preparo Ortocirúrgico

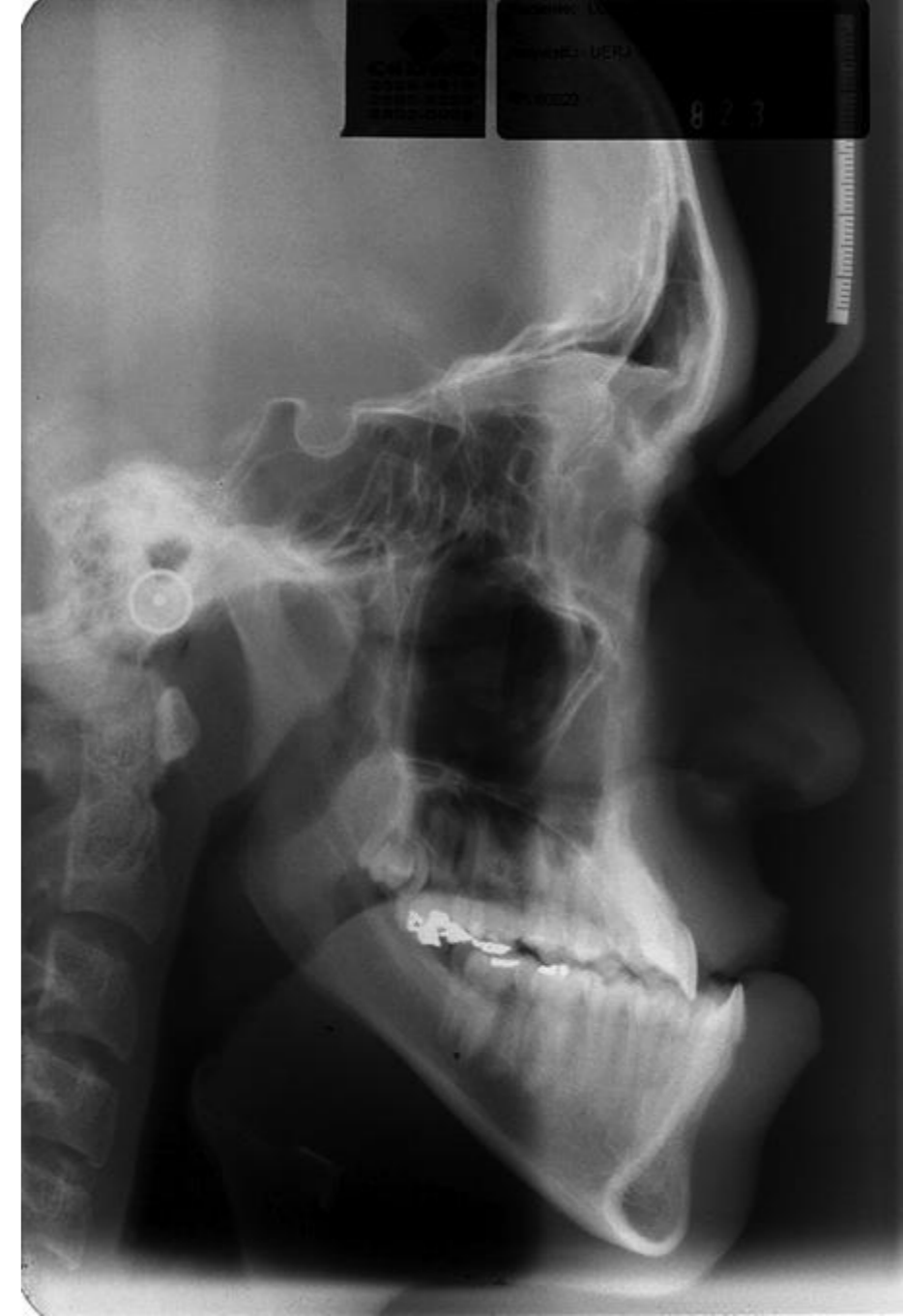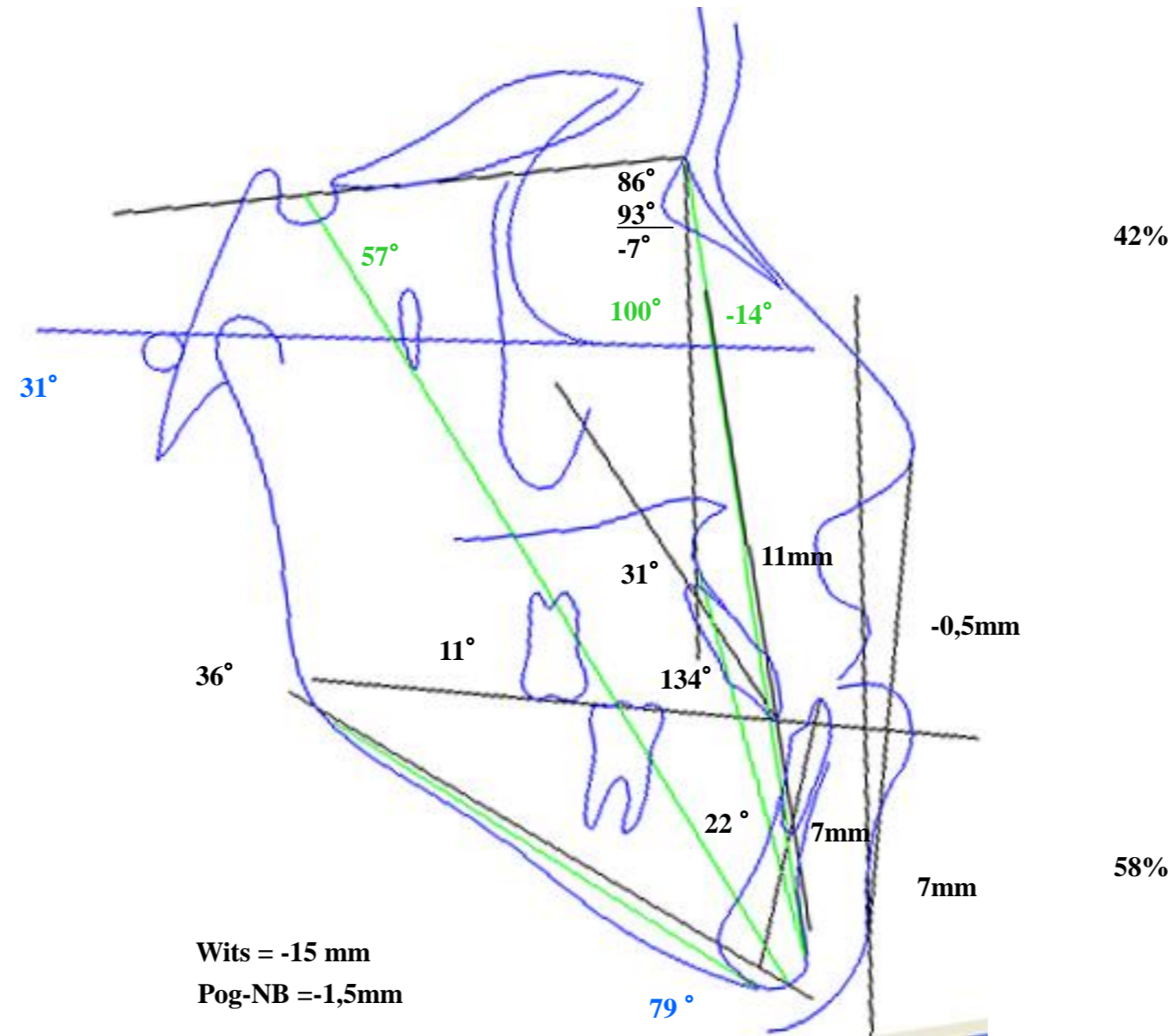




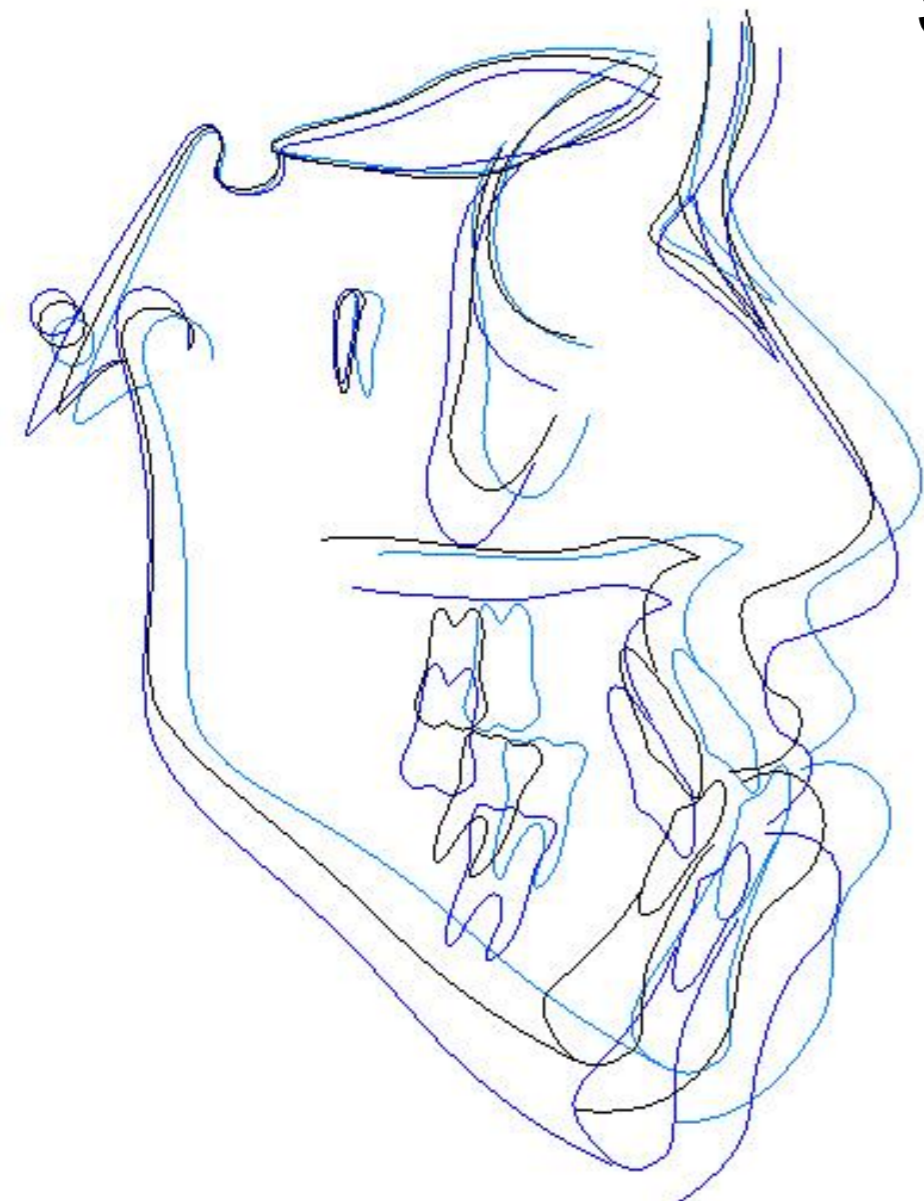ANÁLISE RADIOGRÁFICA




ANÁLISE RADIOGRÁFICA



SOBREPOSIÇÕES TOTAIS



SN com registro em S – Crescimento facial



SN com registro em N - Perfil

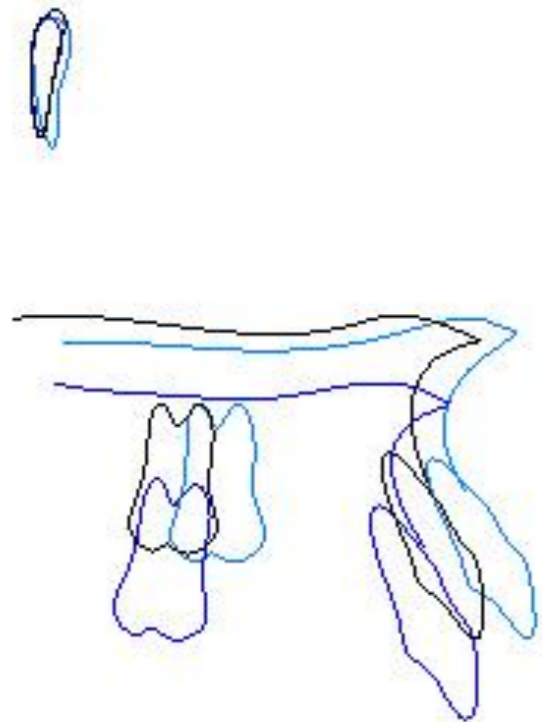



2004

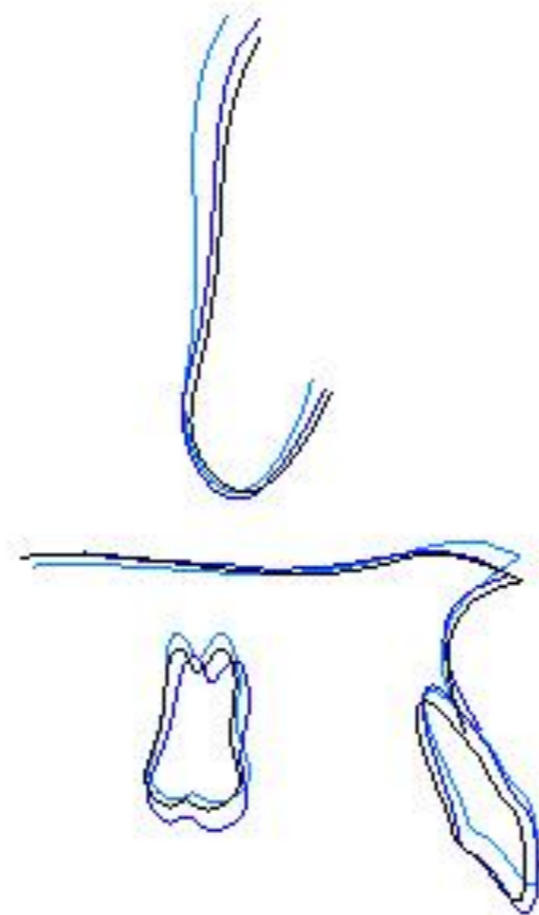
2005

2008

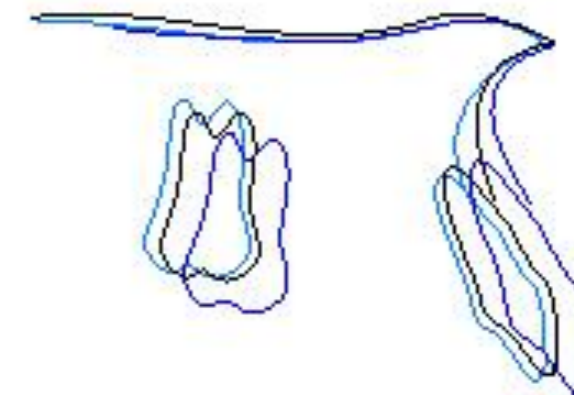
SOBREPOSIÇÕES PARCIAIS DE MAXILA



SN com registro em Ptm –
Crescimento AP da maxila

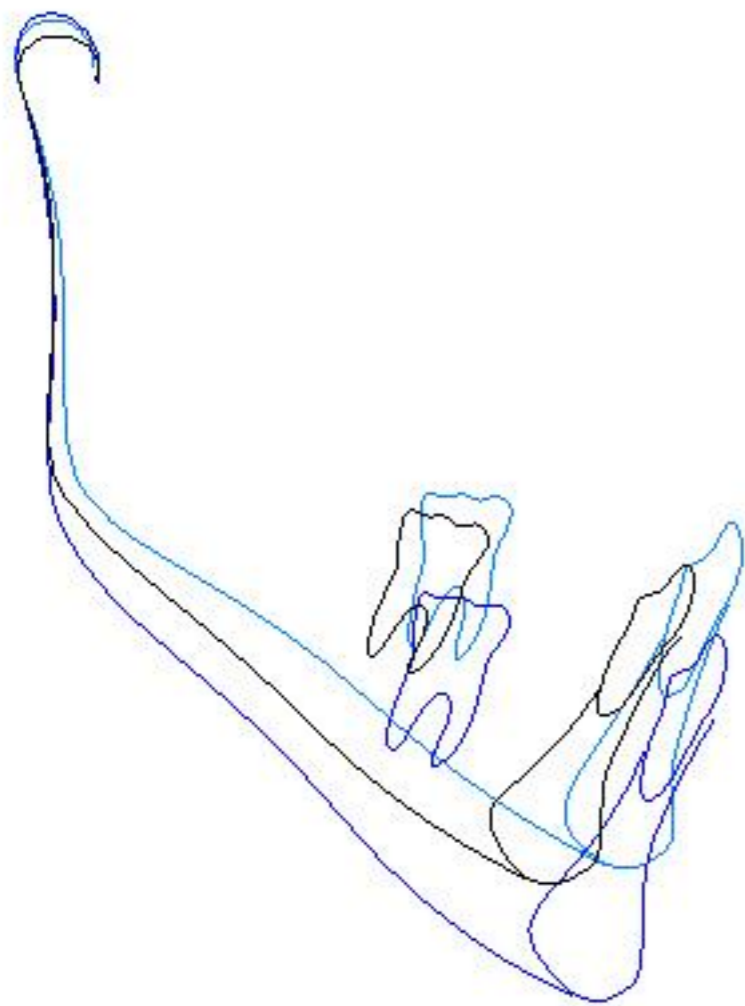



SN com registro em K.R. –
Crescimento vertical da maxila

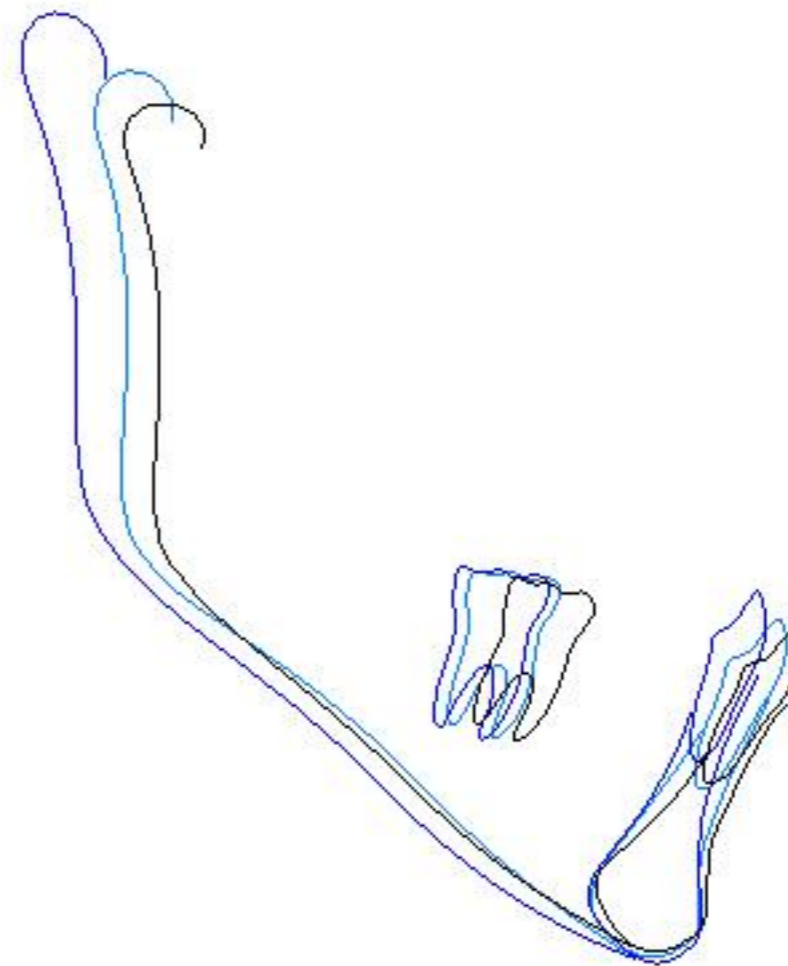


Best Fit da maxila –
Movimentação dentária

SOBREPOSIÇÕES PARCIAIS DE MANDÍBULA



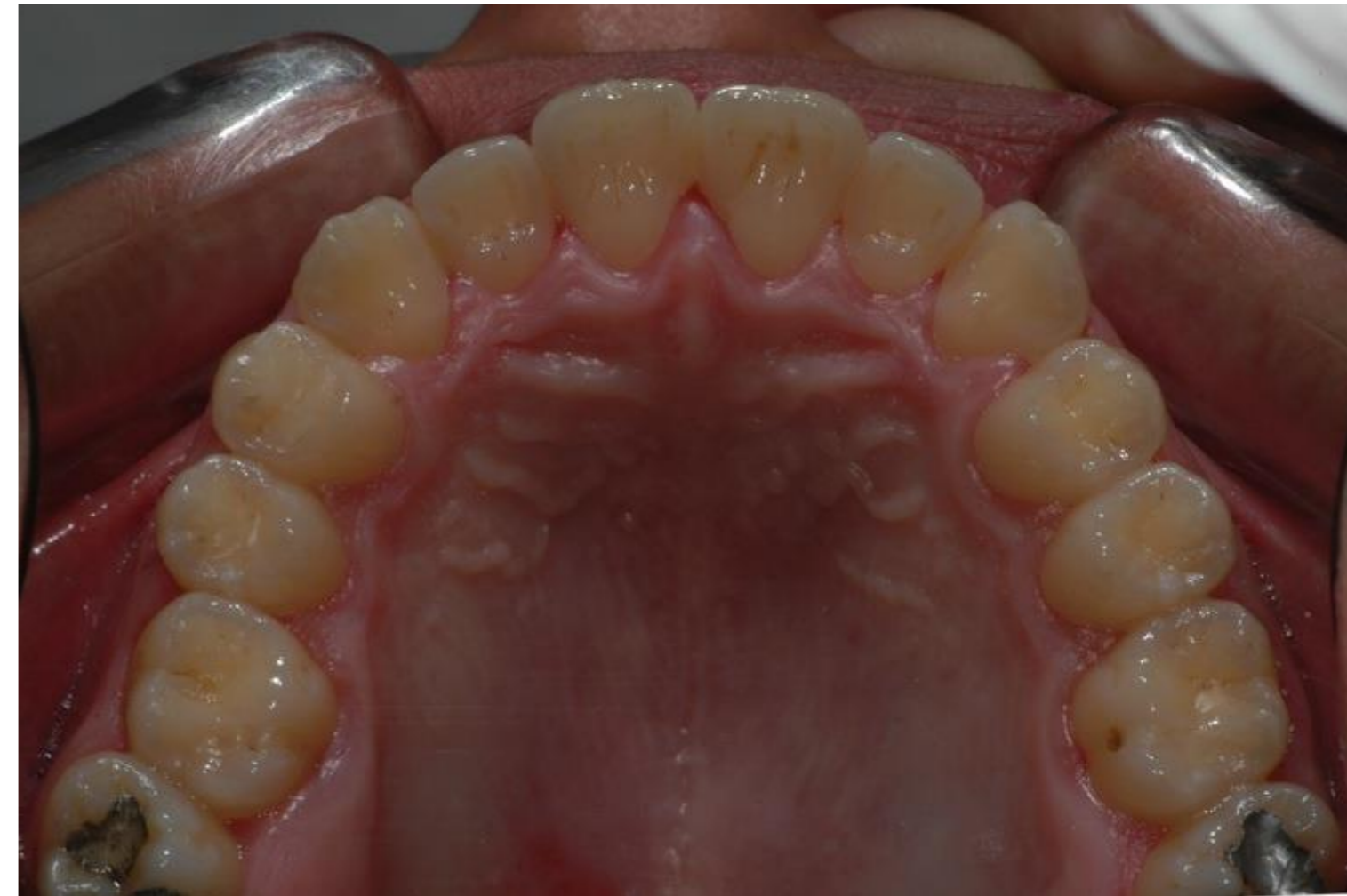SN com registro em AR –
Crescimento AP e vertical da mandíbula



Go-Gn com registro em D –
Movimentação dentária

PLANO DE TRATAMENTO – ARCO SUPERIOR

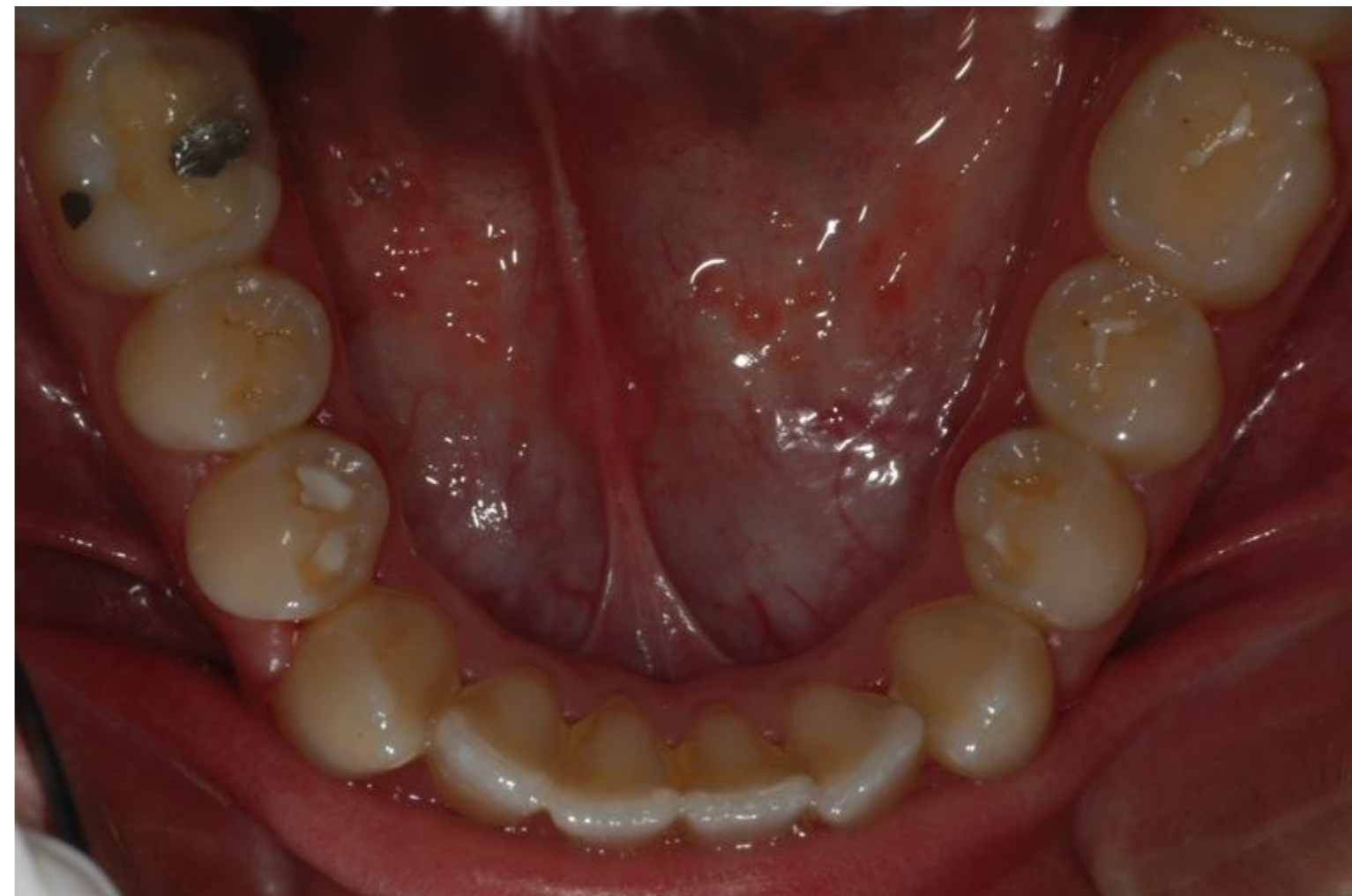- CoCi 16, 17, 26 e 27
- Colagem de 15 a 25
- AINi: NiTi .014"; .016"; Multibraid .017"x.025", Aço .019"x.025";
- Soldagem de spurs no Aço .019"x.025" p/ cirurgia ortognática de recuo mandibular + avanço maxilar
- * Avaliar a necessidade do uso de um arco vestibular expandido p/ auxiliar no descruzamento do 16
- Arco Aço .019"x.025" de finalização.



Contenção: Wraparound

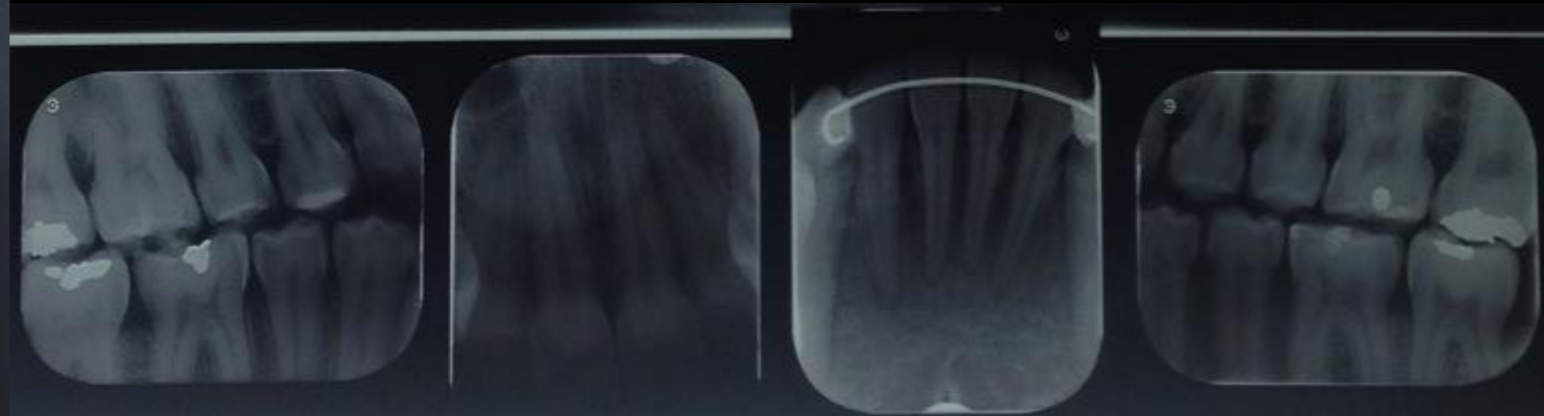
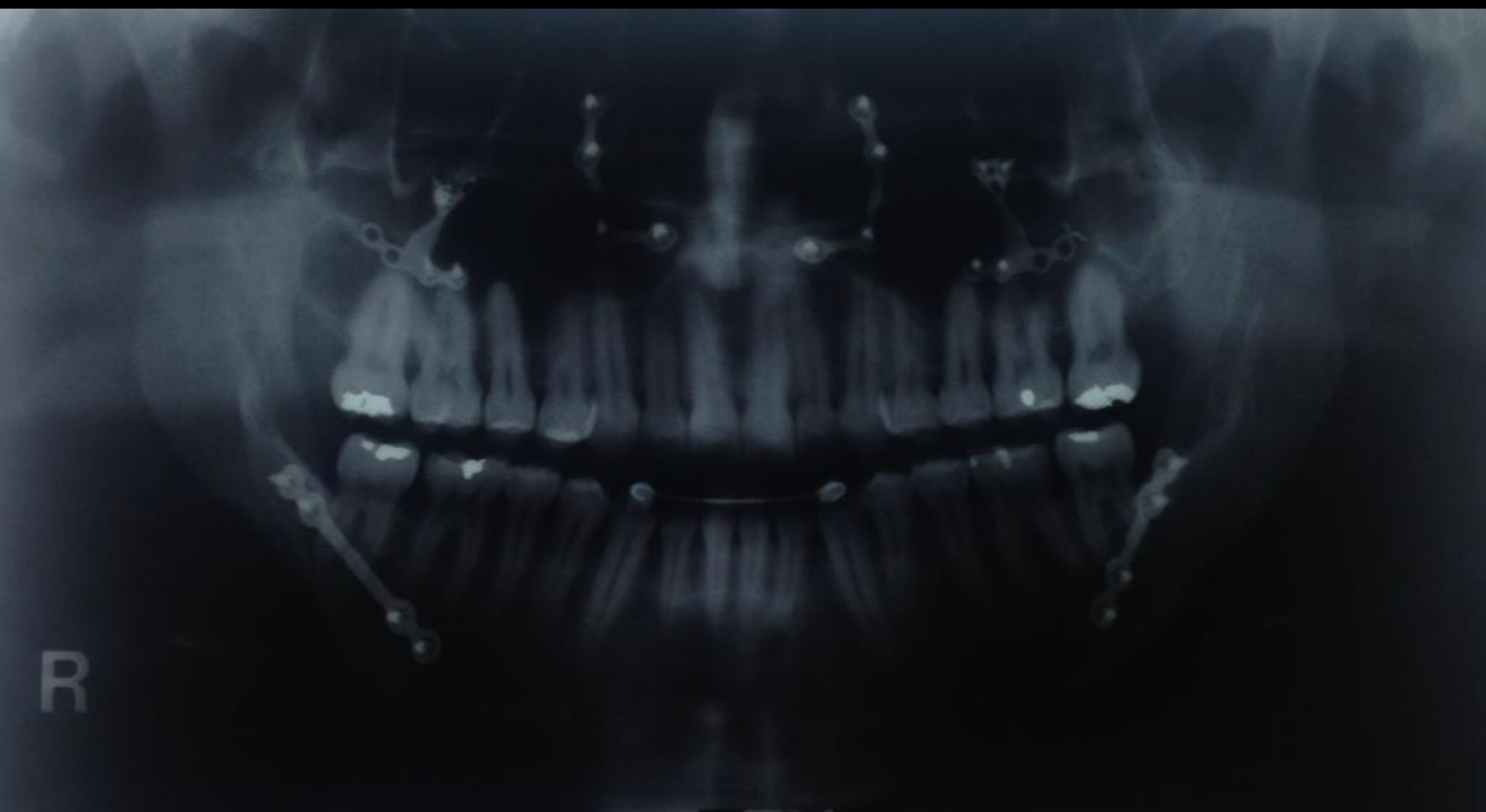PLANO DE TRATAMENTO – ARCO INFERIOR

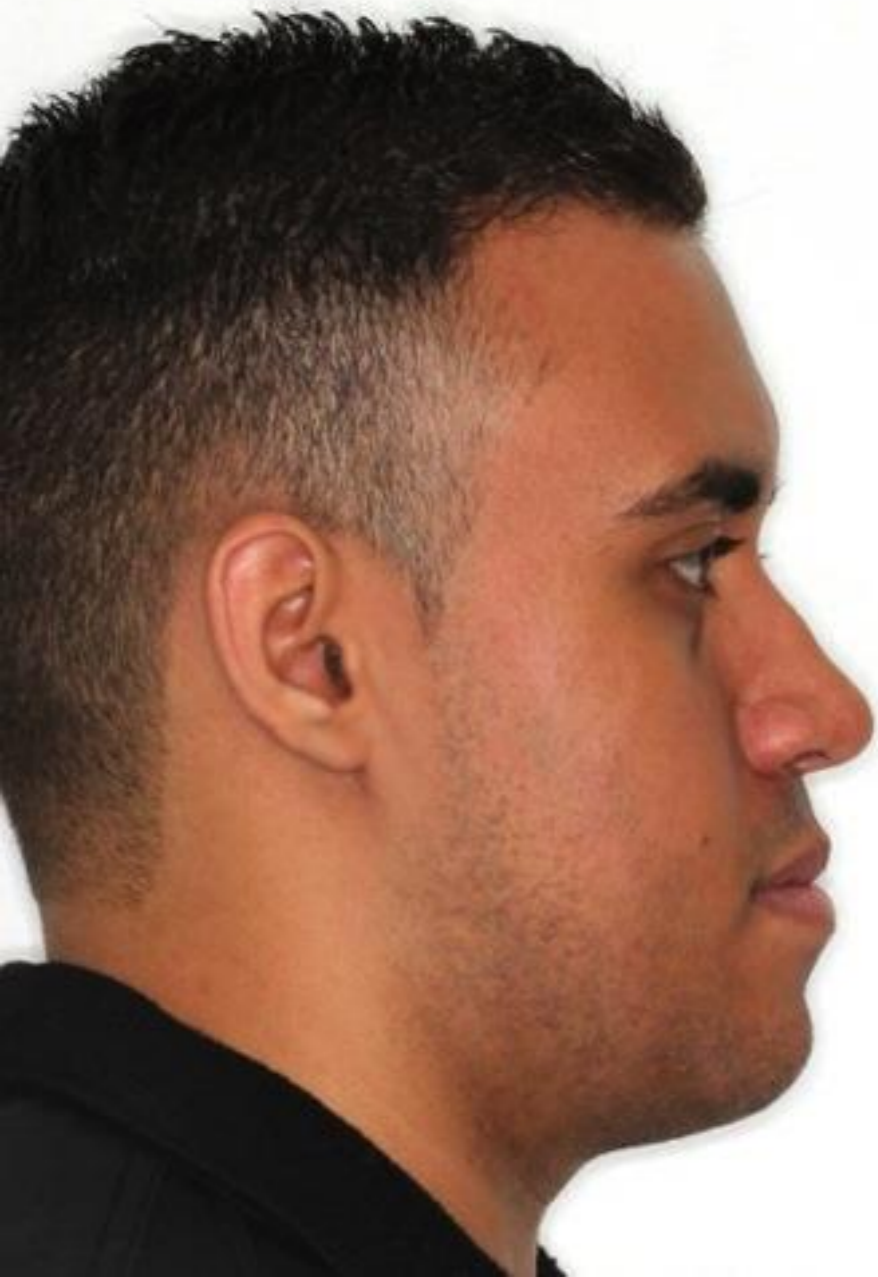- CoCi 36, 37, 46 e 47
- Colagem de 35 a 45
- AINi: NiTi .014"; .016"; Multibraid .017"x.025"; Aço .019"x.025";
- Soldagem de spurs no Aço .019"x.025" p/ cirurgia ortognática
- Arco Aço .019"x.025" de finalização.



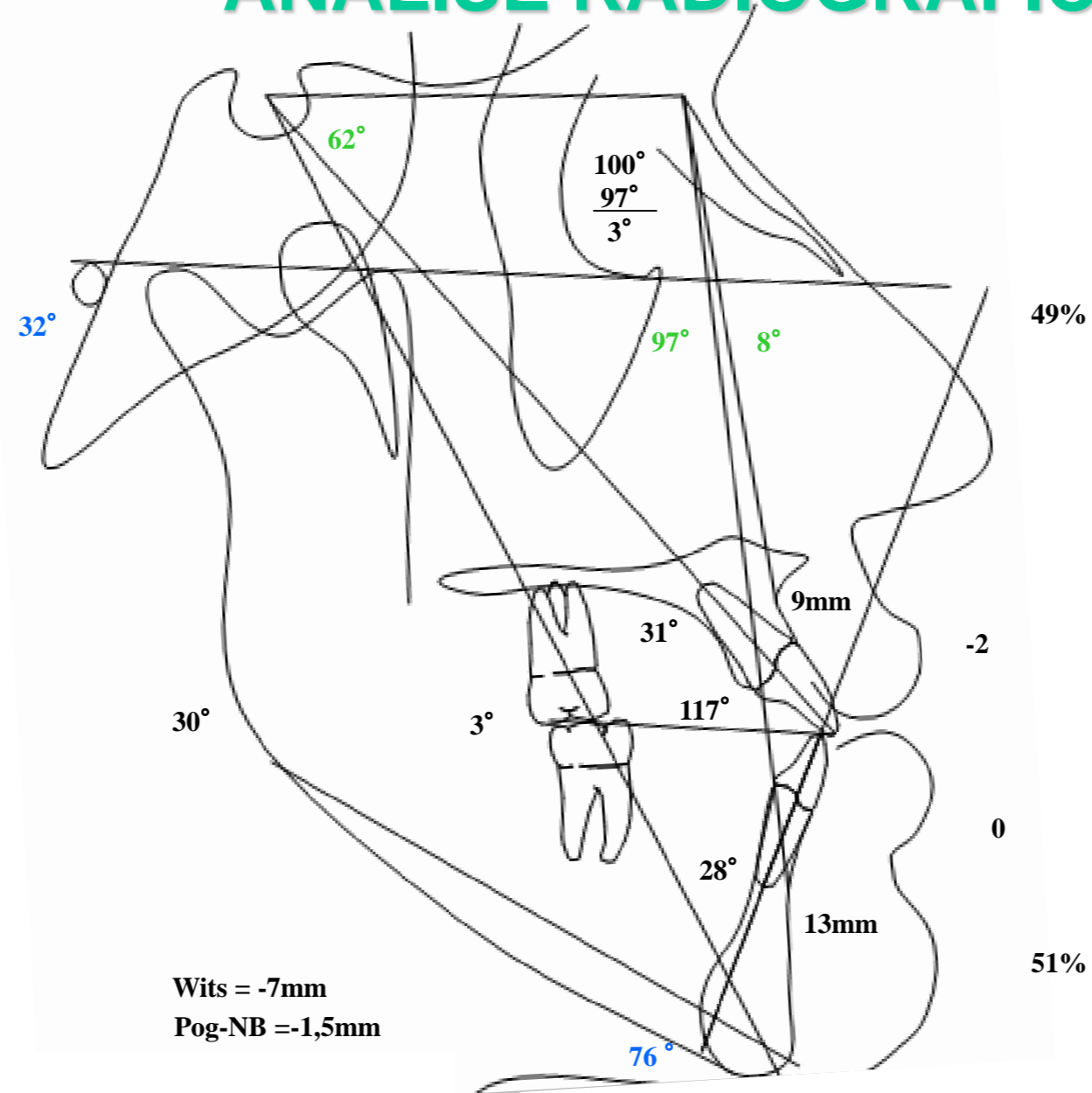
Contenção: Barra 3x3

ANÁLISE RADIOGRÁFICA

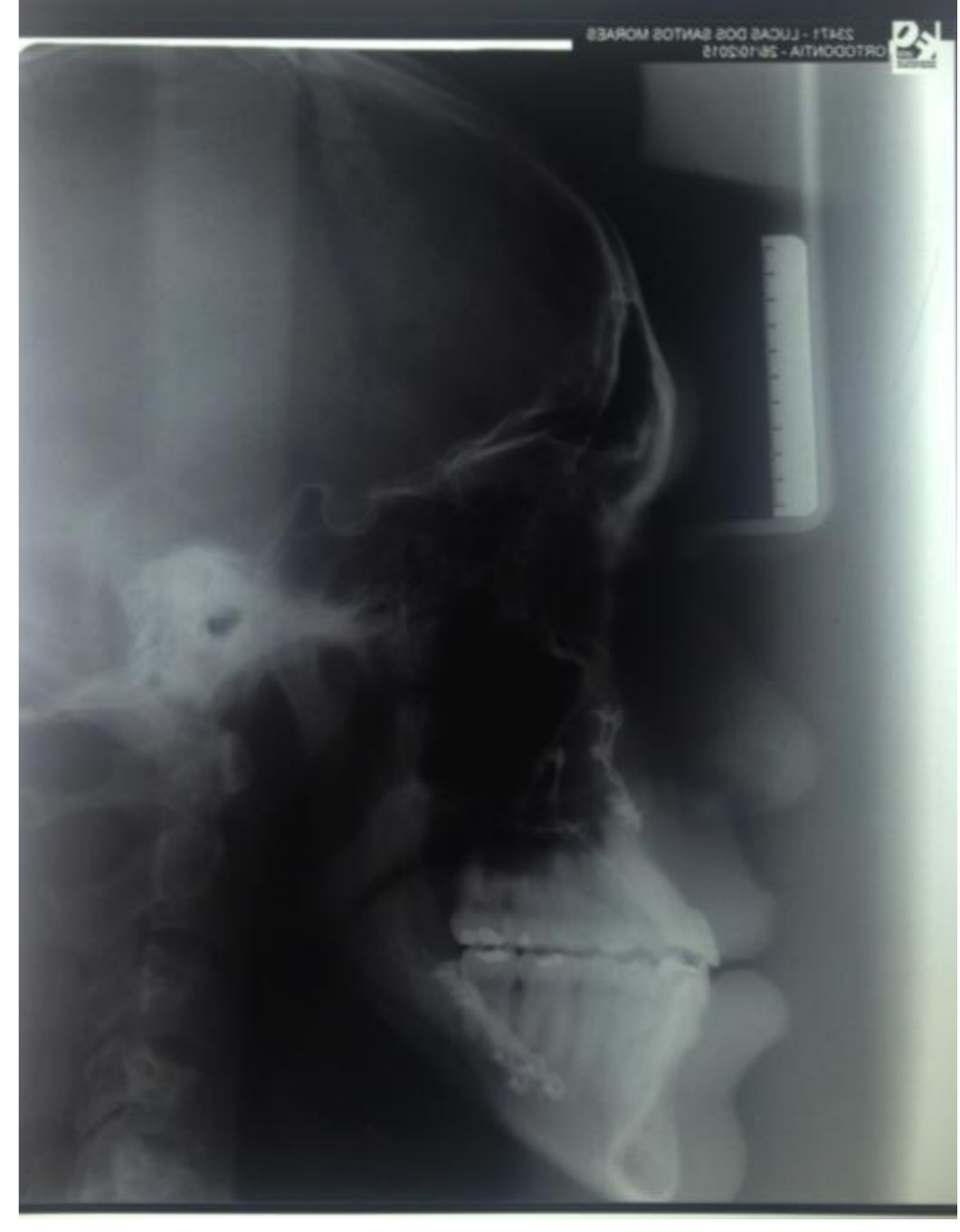



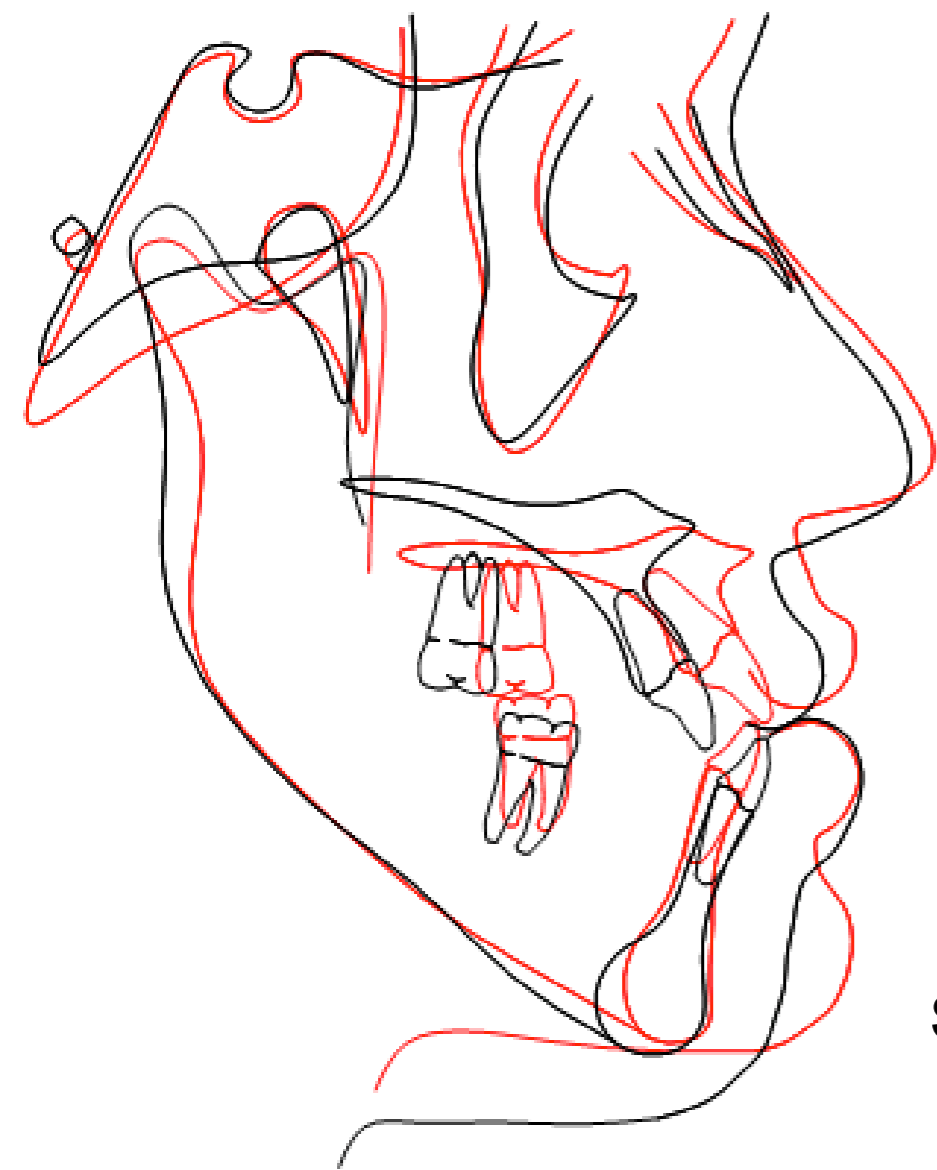
ANÁLISE RADIOGRÁFICA




Wits = -7mm
Pog-NB = -1,5mm



SOBREPOSIÇÕES TOTAIS (2008 - 2015)

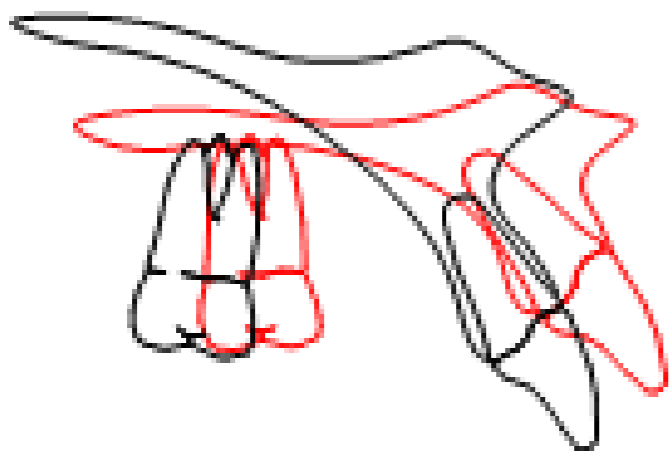
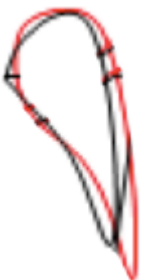

**SN com registro em S
Crescimento Total**

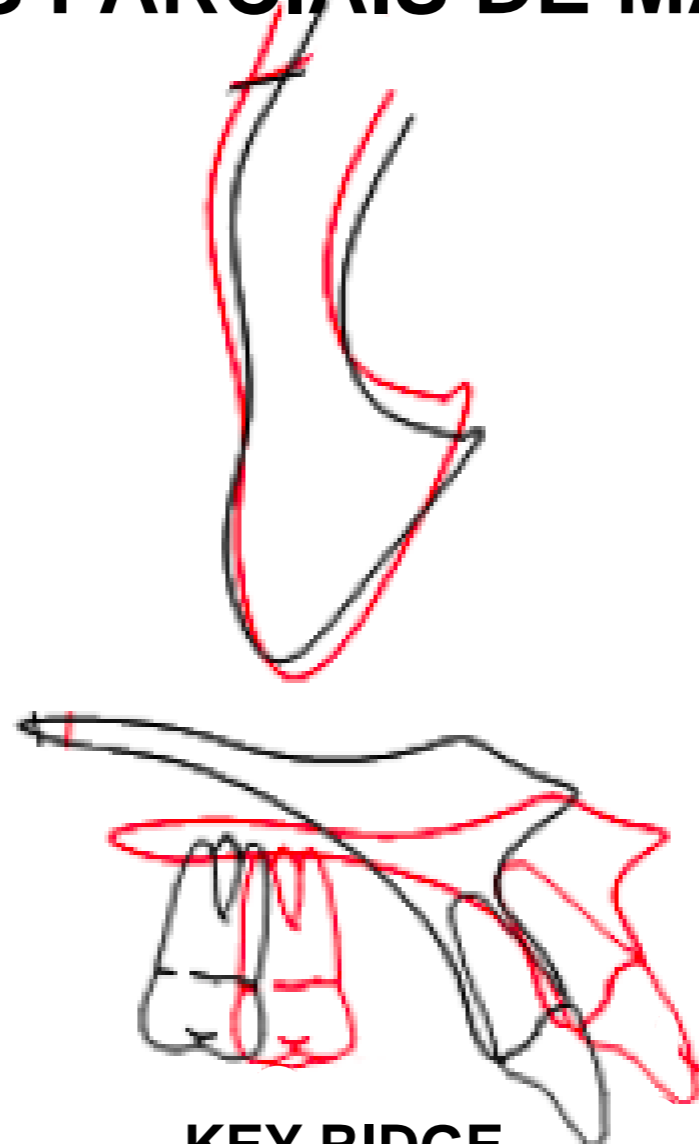


**SN com registro em N
Perfil**

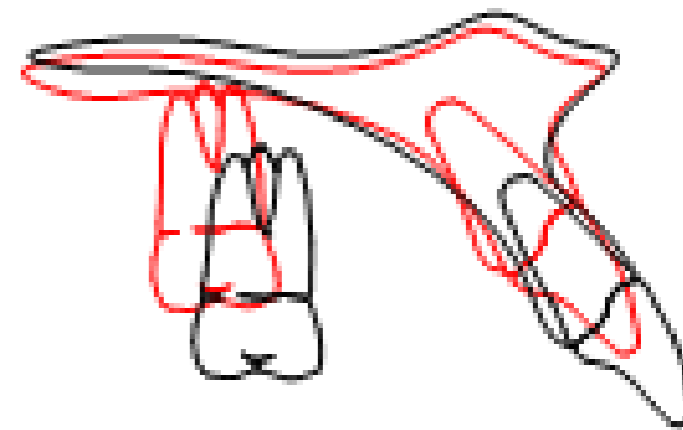
SOBREPOSIÇÕES PARCIAIS DE MAXILA (2008 - 2015)



PTM
Crescimento AP

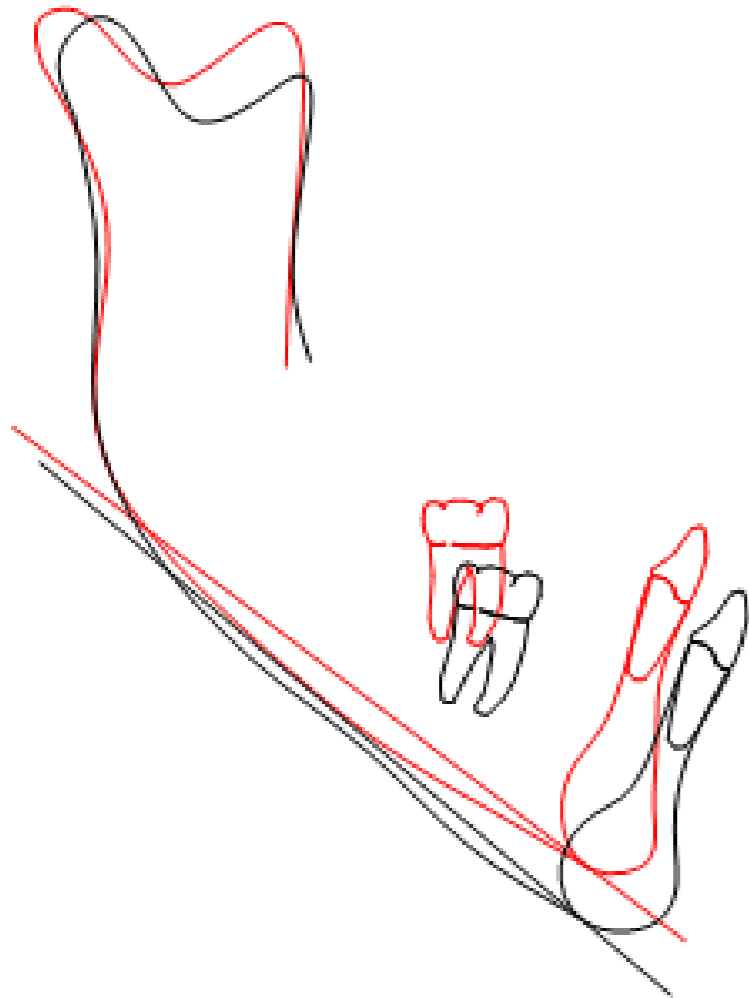


KEY RIDGE
Crescimento Vertical

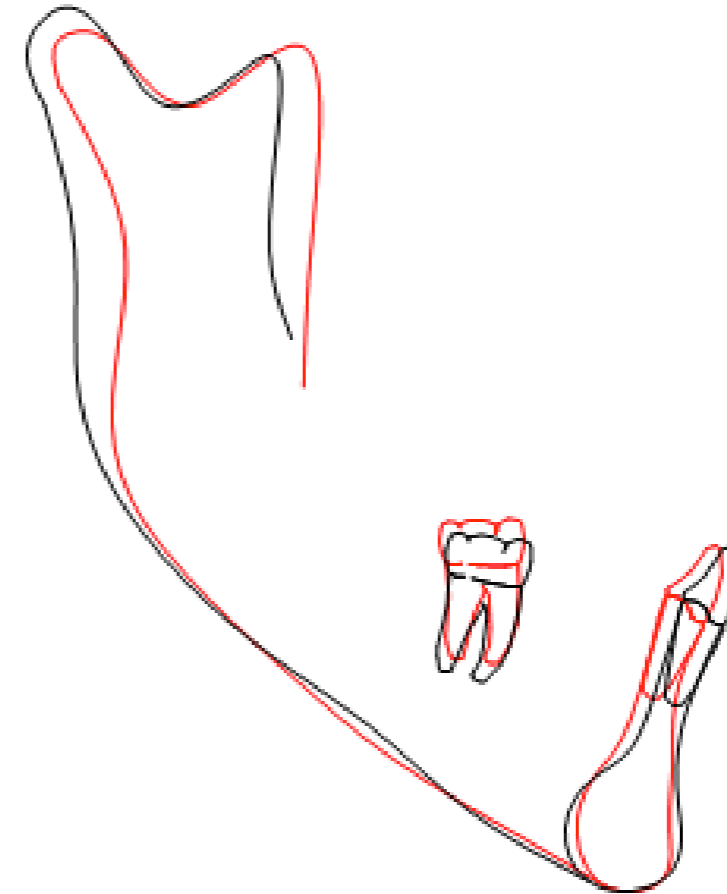


BEST FIT
Movimento Dentário

SOBREPOSIÇÕES PARCIAIS DE MANDÍBULA (2008 - 2015)



Registro em Ar
Crescimento AP e Vertical



Contorno interno da Sínfise
Movimento Dentário



